

## Clinical Case1

### Learning Objectives:

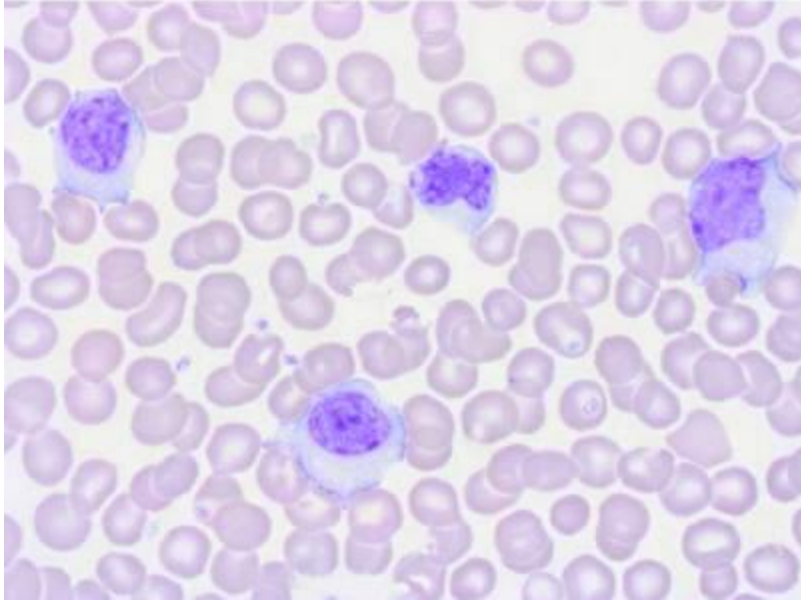
*By the end of the CBL, students will be able to*

1. Interpret the report of Complete Blood Count.
2. Identify abnormalities in a Complete Blood Count.

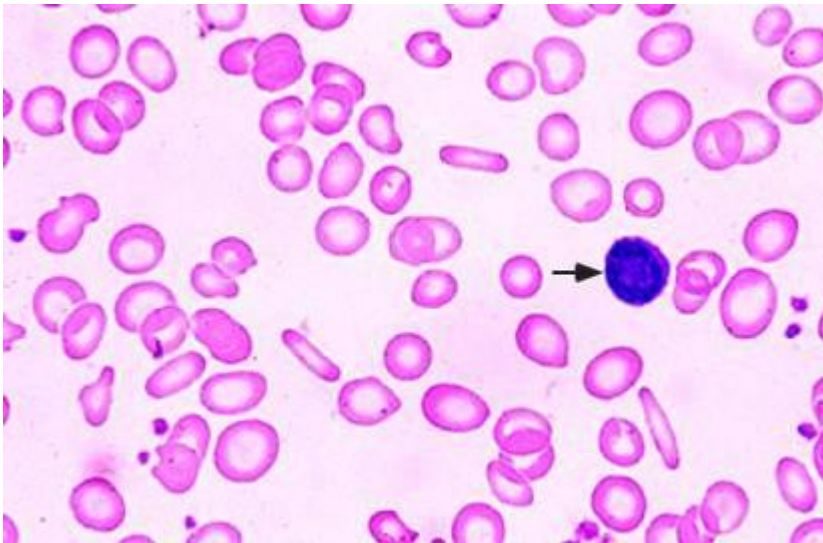
A 28-years-old professional lady, resident of Karachi , is in the first trimester of her first pregnancy. Though her pregnancy has been progressing uneventfully, recently she has noticed that she gets tired easily and is short of breath on even slight exertion. She also has experienced periods of light-headedness, though not to the point of fainting. Further she has noticed cramps in her legs, a desire to crunch on ice, and that her tongue has become sore. She is concerned so she makes an appointment to see her physician.

On examination the physician finds that her heart rate is 120/ minute, BP is 100/ 56mmHg, she has pallor, pale gums and nail beds. Given her history and the findings on her physical exam, the physician orders some blood tests. The results are shown below:

Table 1.Complete Blood count	
Red Blood Cell Count	3.5 million/mm <sup>3</sup>
Hemoglobin (Hb)	6.7 g/dl
Hematocrit	23.3%
Mean corpuscular volume ( MCV)	62fL
Mean Corpuscular Hb Concentration (MCHC)	30g/dl
Mean Corpuscular Hb (MCH)	19.0pg/cell
White blood cell count	5.300/uL
Platelet count	5,50,000/L
Reticulocyte count	1.4



Normal Peripheral film



Abnormal Peripheral Film